

# Determination of Placental Weight Using Two-dimensional Sonography and Volumetric Mathematic Modeling

Humberto Azpurua, M.D.,<sup>1</sup> Edmund F. Funai, M.D.,<sup>1</sup> Luisa M. Coraluzzi,<sup>1</sup> Leo F. Doherty, M.D.,<sup>1</sup> Isaac E. Sasson, M.D.,<sup>1</sup> Merwin Kliman, M.S.E.E.,<sup>2</sup> and Harvey J. Kliman, M.D., Ph.D.<sup>1</sup>

## ABSTRACT

An abnormally decreased placental weight has been linked to increased perinatal complications, including intrauterine fetal demise (IUFD) and fetal growth restriction (IUGR). Despite its promise, determining placental weight prenatally using three-dimensional systems is time-consuming and requires expensive technology and expertise. We propose a novel method using two-dimensional sonography that provides an immediate estimation of placental volume. Placental volume was calculated in 29 third-trimester pregnancies using linear measurements of placental width, height, and thickness to calculate the convex-concave shell volume within 24 hours of birth. Data were analyzed to calculate Spearman's rho ( $r_s$ ) and significance. There was a significant correlation between estimated placental volume (EPV) and actual placental weight ( $r_s = 0.80$ ,  $p < 0.001$ ). Subgroup analysis of preterm gestations ( $n = 14$ ) revealed an even more significant correlation of EPV to actual placental weight ( $r_s = 0.89$ ,  $p < 0.001$ ). Placental weight can be accurately predicted by two-dimensional ultrasound with volumetric calculations. This method is simple, rapid, and accurate, making it practical for routine prenatal care, as well as for high-risk cases with decreased fetal movement and IUGR. Routine EPV surveillance may decrease the rates of perinatal complications and unexpected IUFD.

**KEYWORDS:** Placenta, volume, ultrasound, IUFD, IUGR

A healthy baby at term is the product of three important factors: a healthy mother, normal genes, and good placental implantation and growth.<sup>1</sup> Currently the focus of prenatal surveillance is the fetus.<sup>2-4</sup> Much effort has been directed toward the detection and assessment of intrauterine growth restriction (IUGR).<sup>5-8</sup> The many cases of IUGR have traditionally been subdivided into

fetal, placental, and maternal. It is clear that a normally functioning placenta is critical for normal fetal growth and development.<sup>9,10</sup> Adequate fetal growth depends on the efficient delivery of nutrients from the mother to the fetus and therefore requires normal uterine perfusion, normal transplacental exchange of nutrients and waste, and normal umbilical blood flow.<sup>11-13</sup> Placental

<sup>1</sup>Department of Obstetrics, Gynecology, and Reproductive Sciences, Yale University, New Haven, Connecticut; <sup>2</sup>Department of Mathematics, Hofstra University, Hempstead, Long Island.

Address for correspondence and reprint requests: Harvey J. Kliman, M.D., Ph.D., Department of Obstetrics, Gynecology, and Reproductive Sciences, Yale University School of Medicine, Suite 770, 300 George Street, New Haven, CT 06511 (e-mail: harvey.kliman@

yale.edu).

Am J Perinatol. Copyright © by Thieme Medical Publishers, Inc., 333 Seventh Avenue, New York, NY 10001, USA. Tel: +1(212) 584-4662.

Received: February 25, 2009. Accepted: May 11, 2009.  
DOI 10.1055/s-0029-1234034. ISSN 0735-1631.

thickness<sup>14</sup> and volume have been used to predict chromosomal anomalies<sup>15</sup> and diseases such as pre-eclampsia,<sup>16</sup> thalassemia,<sup>17</sup> and other complications of pregnancy.<sup>18–20</sup>

Currently, sonographic assessment of placental volume is time-consuming and requires expensive technology. The best approach thus far has been three-dimensional ultrasound measurements; but this technique requires specialized training.<sup>15,16,21</sup> Placental volume assessment is therefore uncommon in routine obstetric practice, a lack that prevents obstetricians from identifying their patients with extremely small placentas. This is a population who are at risk of sudden intrauterine fetal demise.<sup>22</sup>

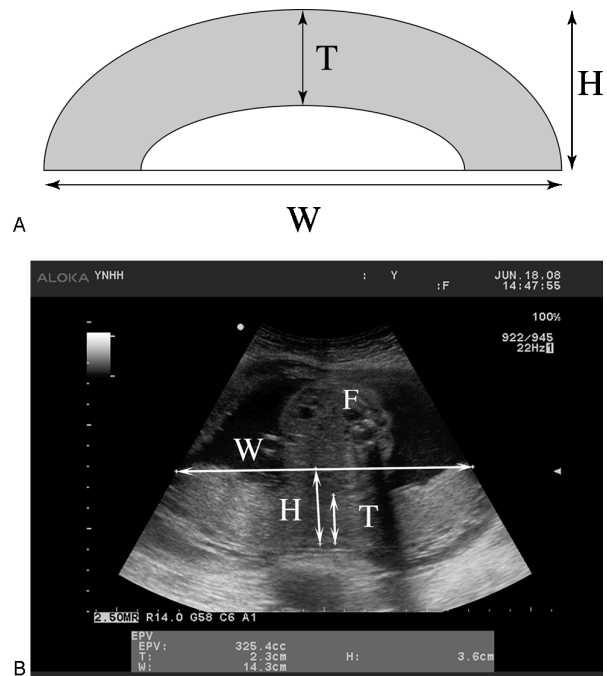
We propose a new method of calculating placental volumes using widely accessible two-dimensional ultrasound measurements and a mathematical equation. The aim of our study was to correlate the results of this new sonographic method to the actual placental weight and volume at birth. We also investigated technical aspects of these measurements to assess their reliability and reproducibility.

## METHODS

We prospectively studied singleton pregnancies in women with indicated elective cesarean sections or in patients at risk of preterm delivery. Informed consent was obtained and the study was approved by the Human Investigation Committee at Yale University (protocol number 0610001963).

A total of 38 patients consented to participate in this study. Fourteen studies were performed in preterm (< 37 weeks) and 24 in full-term (≥ 37 weeks) pregnancies. For preterm participants, inclusion criteria consisted of singleton pregnancy, uterine contractions refractory to tocolysis, and advanced cervical dilatation (3 cm or more). For full-term participants, inclusion criteria consisted in a singleton pregnancy scheduled for a cesarean section in less than 24 hours after the volume estimation. Exclusion criteria included presence of fibroids, rupture of membranes, oligohydramnios, placenta previa and other placental anomalies, history of vaginal bleeding less than 1 month before the study, and maternal medical complications. In all cases, gestational age was established based on an ultrasonographic examination before 20 weeks. All ultrasounds were performed by the same operator (H.A.) at Yale New Haven Hospital with an Aloka ProSound α10 system (Aloka, Tokyo, Japan) equipped with a 4- to 8-MHz curved array transducer.

Placental location and shape were assessed using standard two-dimensional ultrasound techniques. Placental thickness was measured, when possible, at the level of the cord insertion, thus maintaining close proximity to the perpendicular of the placental surface.



**Figure 1** (A) Diagram showing parameters measured to calculate estimated placental volume (EPV). (B) Representative scan used to generate EPV. W, maximal width; H, height at maximal height; T, thickness at maximal height; F, fetus.

Maximal width and height were acquired in an image of the placenta using the scheme illustrated in Fig. 1. If necessary, the probe was slightly angled to allow full visualization of both placenta edges simultaneously.

Measurements to estimate placental volume used the following convex-concave shell formula:  $V = (\pi T/6) * [4H(W - T) + W(W - 4T) + 4T^2]$ , where  $V$  = volume;  $W$  = maximal width;  $H$  = height at maximal height;  $T$  = thickness at maximal height. Harmonic imaging was used as needed to provide clear contrast between tissue structures. We optimized the probe to achieve the maximum angle and varied the depth of penetration to optimize the field of view of the placenta. We collected the length measurements only when we were able to visualize both edges of the placenta evenly. Reproducibility was assessed by performing three independent estimated placental volume (EPV) assessments at different times on five different patients. Amniotic fluid was evaluated, obtaining the sum of the maximal vertical pocket in four quadrants and expressed as amniotic fluid index.

After delivery, the umbilical cord was immediately clamped at its placental insertion to prevent loss of fetal blood, the maternal surface was dried with a towel, and the membranes were carefully trimmed at the placental margin. Each placenta was weighed within 24 hours of EPV measurement and within 15 minutes from delivery, with an accuracy of  $\pm 5$  g (Scale-tronix 4800; Wheaton, IL). Major (A) and minor (B) diameters

and height (H) were measured on a flat surface, which were then used to calculate actual placental volume using the formula for an elliptical cylinder, where  $V = \pi ABH$ . Data were collected on an Excel spreadsheet (Microsoft, Redmond, WA) and analyzed using SPSS for windows, version 15.0 (Chicago, IL). A scatter graph was obtained, and Spearman's rho ( $r_s$ ) was used to compare the EPV to the actual placental weight (APW) and volume (APV). The coefficients of variation were calculated by performing five repeated measurements on three patients, using the formula: standard deviation/mean  $\times$  100. The mean error was calculated by taking the mean value of all the positive and negative errors without regard to sign.

## RESULTS

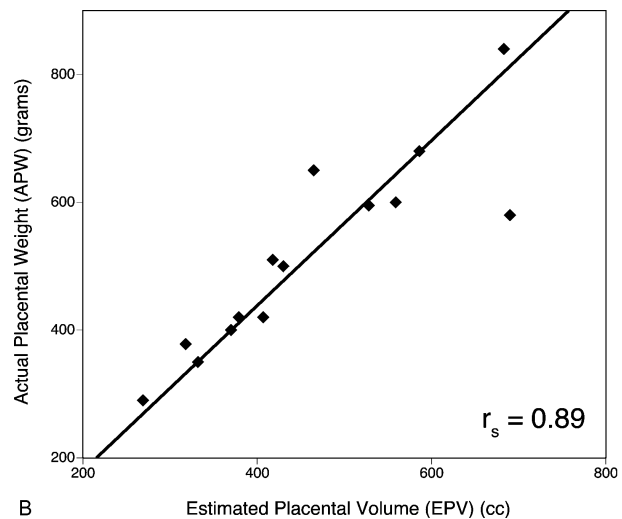
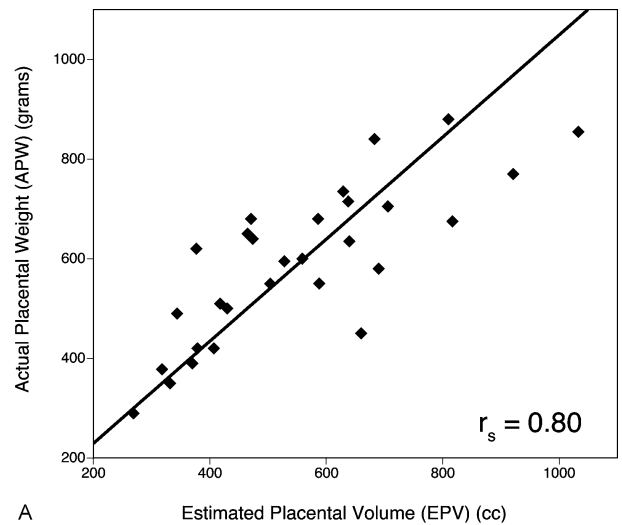
Among the 38 patients who consented, nine placentas could not be evaluated properly either due to a body mass index  $>35$  ( $n = 3$ ) or a very large placenta that did not fit in the ultrasound screen ( $n = 6$ ). The acquisition of the placenta volume was successfully achieved in the remaining patients ( $n = 29$ ) in  $\sim 1$  to 2 minutes for each patient. The maternal age of the study population ranged between 20 and 42 years, gestational age ranged between 29 and 40.7 weeks, and the amniotic fluid index ranged from 8 to 26 cm (Table 1). The intraobserver reproducibility was excellent for placenta volume calculations (intraclass correlation coefficient: 0.99).

There was a significant positive correlation between EPV and APW ( $r_s = 0.80$ ,  $p < 0.001$ ) at all gestational ages examined (Fig. 2A). In the preterm pregnancies, the correlation between EPV and APW was even stronger ( $r_s = 0.89$ ,  $p < 0.001$ ; Fig. 2B). There was also a significant positive correlation between EPV and APV ( $r_s = 0.76$ ,  $p < 0.001$ ). Subanalysis of the full-term placentas revealed a lower correlation between EPV and APW ( $r_s = 0.68$ ,  $p < 0.001$ ). The mean error was 16% among all the patients, 19% for the term cases, and 13% for the preterm cases. When placental location was analyzed regarding the difficulty of visualization, no differences were found between fundal, anterior, or posterior placentas. The placentas examined in this study were minimally elliptical, with a mean minor to major axis ratio of  $0.96 \pm 0.08$ .

**Table 1 Demographic Characteristics of the Study Population ( $n = 29$ )**

Variable	Median	Range	SD
Maternal age (y)	32.9	20–42	4.7
Parity	1	0–3	0.8
Gravidity	2.4	1–6	0.4
Gestational age at scan	36.2	29–40.7	3.5
Amniotic fluid index (cm)	12.5	8–26	3.7

SD, standard deviation.



**Figure 2** Correlation of estimated placental volume to actual placental weight. (A) Graph of all 29 patients examined revealing a Spearman's rho ( $r_s$ ) of 0.80. Note that as placental weight increases, the data scatter increases. (B) Graph of only patients at less than 37 weeks' gestation. Note that Spearman's rho ( $r_s$ ) is now 0.89 due to the fact that it was significantly easier to visualize these placentas in one ultrasound field.

## DISCUSSION

As is well known, the human placenta is essential for the exchange of substances between the mother and the fetus.<sup>23</sup> It facilitates the transfer of oxygen and nutrients from the maternal circulation into the umbilical vein and transports all the metabolic waste and  $\text{CO}_2$  from the fetal umbilical arteries into the maternal venous circulation. Its normal development during gestation ensures the necessary support for the formation of a healthy fetus.<sup>10</sup> Prior to the general use of ultrasound in prenatal surveillance, placental hormonal levels were used to assess placental function.<sup>24</sup> In the early days of

ultrasound, Grannum et al developed a method of placenta grading in an attempt to evaluate placental-fetal maturation.<sup>25</sup> This approach was displaced by more accurate methods of fetal well-being assessment.<sup>2,26</sup> These assessments have helped reduce the rate of stillbirth from 11.5 per 1000 births in the 1960s to around 5.1 per 1000 births in the 1980s.<sup>27</sup> Despite these improvements in fetal surveillance, stillbirth rates in the United States have been relatively stable over the last 20 years, reaching a plateau of 6.4 per 1000 births in 2002.<sup>28</sup> Advances in prenatal surveillance have focused mainly on the fetus, with little attention paid to the placenta.<sup>5,29-32</sup> However, it is apparent that a significant fraction of stillbirths are secondary to very small placentas.<sup>22,33-36</sup> Therefore, though it is known that prenatal evaluation of placental volumes using ultrasound imaging has the potential to decrease the number of unexpected fetal demises as recognized by Jauniaux et al,<sup>37</sup> accurate assessment of placental volume is not widely available.

Several methods for evaluating placental volume during pregnancy have been tested, including magnetic resonance imaging and three-dimensional ultrasound.<sup>15,38-42</sup> These methods require expensive equipment and specialized training. Furthermore, the time needed to complete such studies may prevent an appropriately speedy response. Due to these factors, placental volume evaluation has not been a standard of daily clinical practice.

Our study validates a simple method to calculate placental volume using widely available two-dimensional ultrasound equipment. Although we have demonstrated that EPV assessment correlates well with actual placental weight, technical difficulties remain, especially with large placentas and in patients with a high body mass index. In 100% of the cases with compromised placental visualization, the gestational age was over 36 weeks. Image quality and accuracy of our measurements were improved when we performed the study at earlier gestational ages (Fig. 2B). Because the method will most likely be targeted to the first and second trimesters of pregnancy, the inability to measure placental volume at advanced gestational ages should not be clinically detrimental.

Because the majority of placentas examined for this study were close to being circular, we cannot comment on the utility of this method on placentas with markedly abnormal shapes. It is possible, for example, that an EPV using either the minor or major axis alone of a very oblong placenta, or one lobe of a bilobed placenta, may result in an erroneous estimate. It would therefore behoove the operator in such cases to examine more closely any placenta that is either significantly large or small for expected placental volume for gestational age to rule out placental shape anomalies.

Current prenatal ultrasound surveillance entails a scan in the first trimester followed by an anatomic evaluation of the fetus between 18 and 20 weeks of gestation.<sup>43</sup> In some cases, this is followed by a growth evaluation of the fetus in the third trimester. Because EPV measurement is simple and rapid, we propose including this procedure to rule out the presence of a placenta that is small for gestational age whenever a patient is evaluated by ultrasound.

#### ACKNOWLEDGMENTS

This study was performed with the financial support from the Reproductive and Placental Research Unit, Yale University School of Medicine and Aloka Co., LTD, Tokyo, Japan. We acknowledge the assistance of Lauren S. Liberti in the preparation of the HIC application, the nursing staff of the Labor and Delivery Unit of Yale New Haven Hospital for help in collecting the samples used in these studies, and the staff of Aloka America, Wallingford, Connecticut, for the loan of the ProSound  $\alpha$ 10 system and assistance with its programming for these studies.

#### REFERENCES

1. Kliman HJ. Behind every healthy baby is a healthy placenta. In: Berman MR, ed. *Parenthood Lost*. Westport, CT: Bergin & Garvey; 2001:130-131
2. Vintzileos AM, Tsapanos V. Biophysical assessment of the fetus. *Ultrasound Obstet Gynecol* 1992;2:133-143
3. Gilbert WM, Danielsen B. Pregnancy outcomes associated with intrauterine growth restriction. *Am J Obstet Gynecol* 2003;188:1596-1599; discussion 1599-1601
4. Garite TJ, Clark R, Thorp JA. Intrauterine growth restriction increases morbidity and mortality among premature neonates. *Am J Obstet Gynecol* 2004;191:481-487
5. Galan HL, Ferrazzi E, Hobbins JC. Intrauterine growth restriction (IUGR): biometric and Doppler assessment. *Prenat Diagn* 2002;22:331-337
6. Bamberg C, Kalache KD. Prenatal diagnosis of fetal growth restriction. *Semin Fetal Neonatal Med* 2004;9:387-394
7. Harkness UF, Mari G. Diagnosis and management of intrauterine growth restriction. *Clin Perinatol* 2004;31:743-764, vi
8. Baschat AA, Harman CR. Antenatal assessment of the growth restricted fetus. *Curr Opin Obstet Gynecol* 2001;13:161-168
9. Kliman HJ. Trophoblast to human placenta. In: *Encyclopedia of Reproduction*. San Diego: Academic Press; 1999:834-846
10. Kliman HJ. The placenta revealed. *Am J Pathol* 1993;143:332-336
11. Baschat AA, Hecher K. Fetal growth restriction due to placental disease. *Semin Perinatol* 2004;28:67-80
12. Rotmensch S, Liberati M, Luo JS, et al. Color Doppler flow patterns and flow velocity waveforms of the intraplacental fetal circulation in growth-retarded fetuses. *Am J Obstet Gynecol* 1994;171:1257-1264

13. Kliman HJ. Uteroplacental blood flow. The story of decidualization, menstruation, and trophoblast invasion. *Am J Pathol* 2000;157:1759-1768
14. Elchalal U, Ezra Y, Levi Y, et al. Sonographically thick placenta: a marker for increased perinatal risk—a prospective cross-sectional study. *Placenta* 2000;21:268-272
15. Metzenbauer M, Hafner E, Schuchter K, Philipp K. First-trimester placental volume as a marker for chromosomal anomalies: preliminary results from an unselected population. *Ultrasound Obstet Gynecol* 2002;19:240-242
16. Hafner E, Metzenbauer M, Höfner D, et al. Comparison between three-dimensional placental volume at 12 weeks and uterine artery impedance/notching at 22 weeks in screening for pregnancy-induced hypertension, pre-eclampsia and fetal growth restriction in a low-risk population. *Ultrasound Obstet Gynecol* 2006;27:652-657
17. Chen M, Leung KY, Lee CP, Tang MH, Ho PC. Placental volume measured by three-dimensional ultrasound in the prediction of fetal alpha(0)-thalassemia: a preliminary report. *Ultrasound Obstet Gynecol* 2006;28:166-172
18. Hafner E, Metzenbauer M, Höfner D, et al. Placental growth from the first to the second trimester of pregnancy in SGA-foetuses and pre-eclamptic pregnancies compared to normal foetuses. *Placenta* 2003;24:336-342
19. Kinare AS, Natekar AS, Chinchwadkar MC, et al. Low midpregnancy placental volume in rural Indian women: a cause for low birth weight? *Am J Obstet Gynecol* 2000;182:443-448
20. Schuchter K, Metzenbauer M, Hafner E, Philipp K. Uterine artery Doppler and placental volume in the first trimester in the prediction of pregnancy complications. *Ultrasound Obstet Gynecol* 2001;18:590-592
21. Mercé LT, Barco MJ, Bau S. Reproducibility of the study of placental vascularization by three-dimensional power Doppler. *J Perinat Med* 2004;32:228-233
22. Hobbins J. Morphometry of fetal growth. *Acta Paediatr Suppl* 1997;423:165-168; discussion 169
23. Enders AC. Anatomy of the placenta and its relationship to function. *Mead Johnson Symp Perinat Dev Med* 1981;(18): 3-7
24. Brown JB. The value of plasma estrogen estimations in the management of pregnancy. *Clin Perinatol* 1974;1:273-291
25. Grannum PA, Berkowitz RL, Hobbins JC. The ultrasonic changes in the maturing placenta and their relation to fetal pulmonary maturity. *Am J Obstet Gynecol* 1979;133:915-922
26. Manning FA, Platt LD, Sapos L. Antepartum fetal evaluation: development of a fetal biophysical profile. *Am J Obstet Gynecol* 1980;136:787-795
27. Fretts RC, Boyd ME, Usher RH, Usher HA. The changing pattern of fetal death, 1961-1988. *Obstet Gynecol* 1992;79: 35-39
28. Silver RM. Fetal death. *Obstet Gynecol* 2007;109:153-167
29. Brodsky D, Christou H. Current concepts in intrauterine growth restriction. *J Intensive Care Med* 2004;19:307-319
30. Craigo SD. The role of ultrasound in the diagnosis and management of intrauterine growth retardation. *Semin Perinatol* 1994;18:292-304
31. Nyberg DA, Abuhamad A, Ville Y. Ultrasound assessment of abnormal fetal growth. *Semin Perinatol* 2004;28:3-22
32. Resnik R. Intrauterine growth restriction. *Obstet Gynecol* 2002;99:490-496
33. Hafner E, Philipp T, Schuchter K, Dillinger-Paller B, Philipp K, Bauer P. Second-trimester measurements of placental volume by three-dimensional ultrasound to predict small-for-gestational-age infants. *Ultrasound Obstet Gynecol* 1998;12:97-102
34. Thame M, Osmond C, Wilks R, Bennett FI, Forrester TE. Second-trimester placental volume and infant size at birth. *Obstet Gynecol* 2001;98:279-283
35. Hafner E, Metzenbauer M, Dillinger-Paller B, et al. Correlation of first trimester placental volume and second trimester uterine artery Doppler flow. *Placenta* 2001;22:729-734
36. Smith GC, Fretts RC. Stillbirth. *Lancet* 2007;370:1715-1725
37. Jauniaux E, Ramsay B, Campbell S. Ultrasonographic investigation of placental morphologic characteristics and size during the second trimester of pregnancy. *Am J Obstet Gynecol* 1994;170(1 Pt 1):130-137
38. Abramowicz JS, Sheiner E. In utero imaging of the placenta: importance for diseases of pregnancy. *Placenta* 2007;28 (Suppl A):S14-S22
39. Duncan KR, Sahota DS, Gowland PA, et al. Multilevel modeling of fetal and placental growth using echo-planar magnetic resonance imaging. *J Soc Gynecol Investig* 2001; 8:285-290
40. Gowland P. Placental MRI. *Semin Fetal Neonatal Med* 2005;10:485-490
41. Wegrzyn P, Faro C, Falcon O, Peralta CF, Nicolaidis KH. Placental volume measured by three-dimensional ultrasound at 11 to 13 + 6 weeks of gestation: relation to chromosomal defects. *Ultrasound Obstet Gynecol* 2005;26:28-32
42. Kubik-Huch RA, Wildermuth S, Cettuzzi L, et al. Fetus and uteroplacental unit: fast MR imaging with three-dimensional reconstruction and volumetry—feasibility study. *Radiology* 2001;219:567-573
43. American College of Obstetricians and Gynecologists. ACOG practice patterns. Routine ultrasound in low-risk pregnancy. Number 5, August 1997. *Int J Gynaecol Obstet* 1997;59:273-278