

Tumor Emboli: A Rare Cause of Acute Pulmonary Hypertension



To the Editor:

A 70-year old man with stage IV prostate cancer presented to our hospital with 10 days of progressive shortness of breath. He was tachycardic, tachypneic, and mildly hypoxemic. Initial blood counts, chemistry, and troponin were normal. An electrocardiogram showed sinus tachycardia without conduction or ischemic changes. A chest x-ray study was unremarkable.

The patient was diagnosed with metastatic prostate cancer the previous year and underwent 6 rounds of treatment with docetaxel. At the time of presentation, he was maintained on the gonadotropin-releasing hormone analog degarelix. Other medications included aspirin and metformin. He was a former smoker.

Initial work-up of the patient's dyspnea and hypoxemia with a computed tomography angiography of the chest was negative for pulmonary embolus. A transthoracic echocardiogram showed preservation of left ventricle structure and function, but a severely dilated right ventricle with an estimated pulmonary artery systolic pressure of 62 mm Hg. Further work-up with a nuclear medicine ventilation perfusion scan showed numerous small bilateral unmatched perfusion defects and one moderately sized unmatched perfusion defect in the right mid-lung (Figure). This result increased suspicion for tumor emboli syndrome as the cause of the patient's acute pulmonary hypertension.

Funding: This research did not receive any specific grant from funding agencies in the public, commercial, or not-for-profit sectors.

Conflict of Interest: ASM: none; TT: Honoraria received for advisory boards from Actelion, Bayer, and United Therapeutics Pharmaceuticals. Research support received for BEAT trial from Lung Biotechnology and for OPSUMIT registry from Actelion Pharmaceuticals.

Authorship: This manuscript is an original work of the authors. It has not been published elsewhere. Both authors had access to the data described in the manuscript, participated in the writing of the manuscript, have seen and approved it, and agree with submission to *The American Journal of Medicine*.

Requests for reprints should be addressed to Anne S. Mainardi, MD, Pulmonary, Critical Care, and Sleep Medicine Section, Department of Internal Medicine, Yale University School of Medicine, 300 Cedar Street, TAC S425, New Haven, CT 06510.

E-mail address: Anne.mainardi@yale.edu

The patient underwent right heart catheterization. His mean pulmonary artery pressure was 37 mm Hg, with a normal pulmonary capillary wedge pressure of 13 mm Hg. During the procedure, blood was aspirated from the right pulmonary artery and sent for analysis. The cytology lab later reported that the blood sample contained malignant cells consistent with high-grade carcinoma.

Shortly after the right heart catheterization, the patient became acutely more hypoxemic and then hypotensive. Continuous norepinephrine and inhaled nitric oxide were initiated. A bedside echocardiogram showed compression of the left ventricle by an extremely dilated right ventricle. The patient became pulseless; his family chose to terminate resuscitation efforts and he died.

Acute pulmonary hypertension can occur when tumor cells embolize to the pulmonary microcirculation, causing obstructive physiology. Signs and symptoms are similar to those seen in pulmonary thromboembolism, including dyspnea, hypoxemia, and cor pulmonale.¹ This patient's risk factors for thromboembolism included malignancy and androgen deprivation therapy.² His initial evaluation, however, excluded this etiology.

The diagnosis of tumor emboli is often overlooked. A recent series showed only 1 of 17 (6%) patients with tumor emboli was diagnosed antemortem.¹ The presence of tumor emboli can be suggested by a typical scintigram pattern of numerous bilateral peripheral subsegmental defects.³ The definitive diagnosis, however, requires pulmonary microvascular sampling and cytological analysis.⁴ A history of malignancy should increase suspicion, but its absence should not exclude consideration of this entity.⁵

To our knowledge, 4 cases of tumor emboli in a patient with prostate cancer have previously been described.⁶⁻⁹ Unfortunately, there remains no treatment for this syndrome, and further investigation is necessary to improve its diagnosis and treatment.

Anne S. Mainardi, MD

Terence Trow, MD

Pulmonary, Critical Care, and Sleep Medicine Section

Department of Internal Medicine

Yale University School of Medicine

New Haven, Conn

<http://dx.doi.org/10.1016/j.amjmed.2016.11.023>

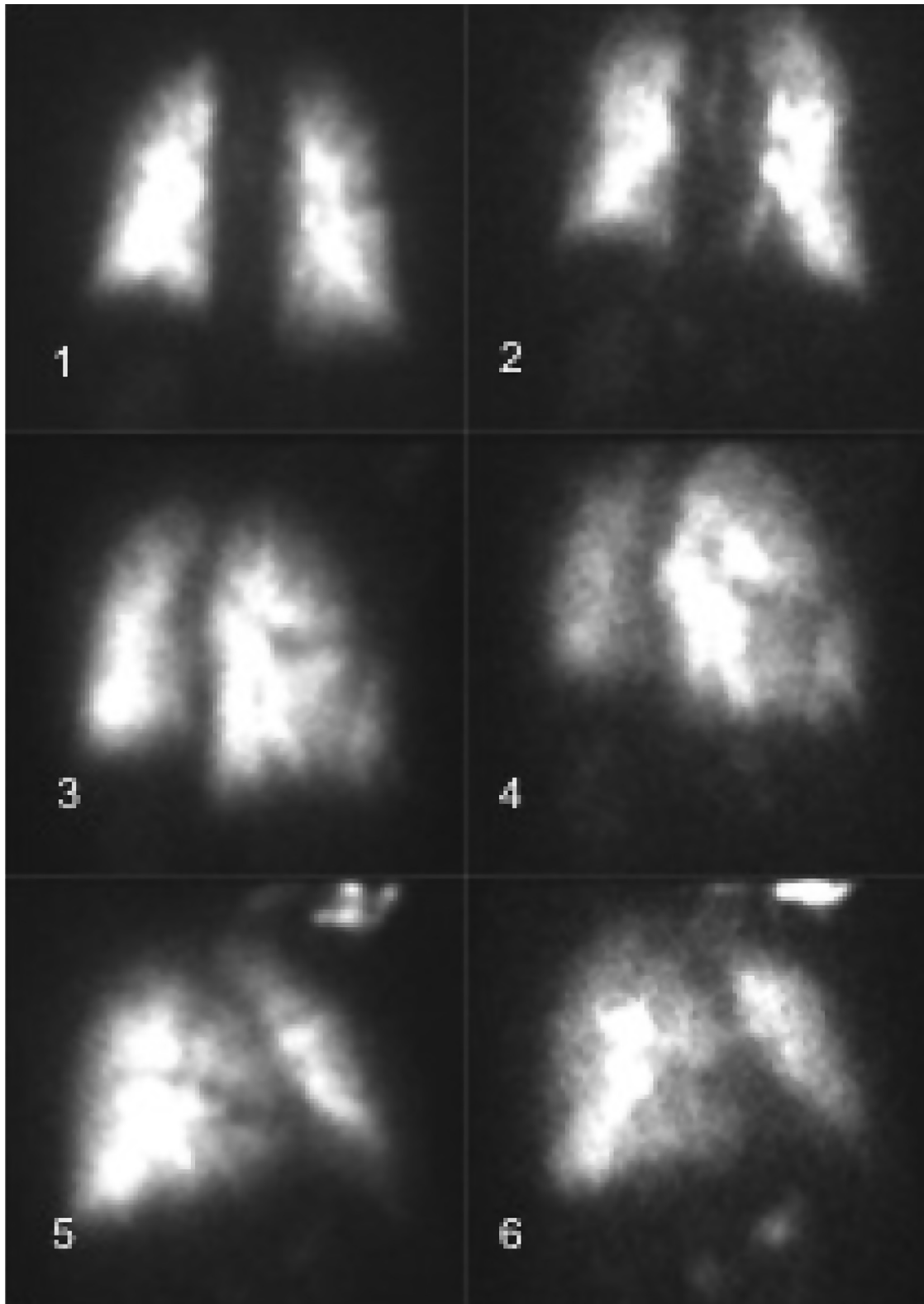


Figure Ventilation perfusion scan showing numerous small bilateral unmatched perfusion defects. (1) anterior posterior (AP) perfusion; (2) AP ventilation; (3) left anterior oblique (LAO) right posterior oblique (RPO) perfusion; (4) LAO RPO ventilation; (5) left posterior oblique (LPO) right anterior oblique (RAO) perfusion; (6) LPO RAO ventilation.

References

1. Storstein O. Circulatory failure in metastatic carcinoma of the lung: a physiologic and pathologic study of its pathogenesis. *Circulation*. 1951;4:913-919.
2. Goldhaber SZ, Dricker E, Buring JE, et al. Clinical suspicion of autopsy-proven thrombotic and tumor pulmonary embolism in cancer patients. *Am Heart J*. 1987;114(6):1432-1435.
3. Shields DJ, Edwards WD. Pulmonary hypertension attributable to neoplastic emboli: an autopsy study of 20 cases and a review of literature. *Cardiovasc Pathol*. 1992;1(4):279-287.
4. Crane R, Rudd TG, Dail D. Tumor microembolism: pulmonary perfusion pattern. *J Nucl Med*. 1984;25(8):877-880.
5. Masson RG, Ruggieri J. Pulmonary microvascular cytology. A new diagnostic application of the pulmonary artery catheter. *Chest*. 1985;88(6):908-914.
6. Bergmann I, Weiss M, Schaffner T. Pulmonary microscopic tumor embolism syndrome. *Dtsch Med Wochenschr*. 2006;131(12):618-621.
7. Miedema EB, Redman JF. Microscopic pulmonary embolization by adenocarcinoma of prostate. *Urology*. 1981;18(4):399-401.
8. Keeping IM, Buchanan R, Dadds JH. Microscopic tumour emboli from carcinoma of the prostate. *Br J Dis Chest*. 1982;76:298-300.
9. Nakano M, Miwa K, Kanimoto Y, Ishihara S, Deguchi T. Microscopic pulmonary tumor embolism secondary to adenocarcinoma of the prostate. *Hinyokika Kyo*. 2003;49(3):169-172.