

Hard to swallow

Complications from a barium esophagram

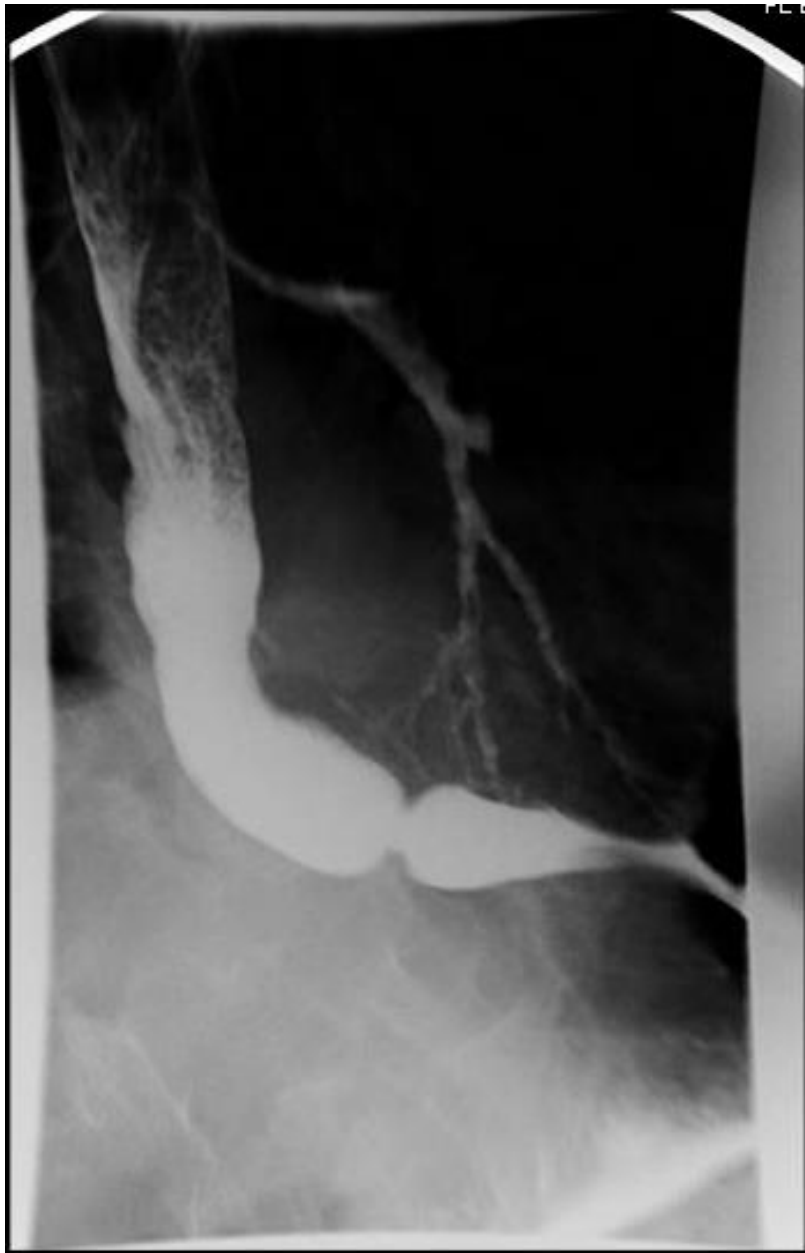David Goldstein, MS4

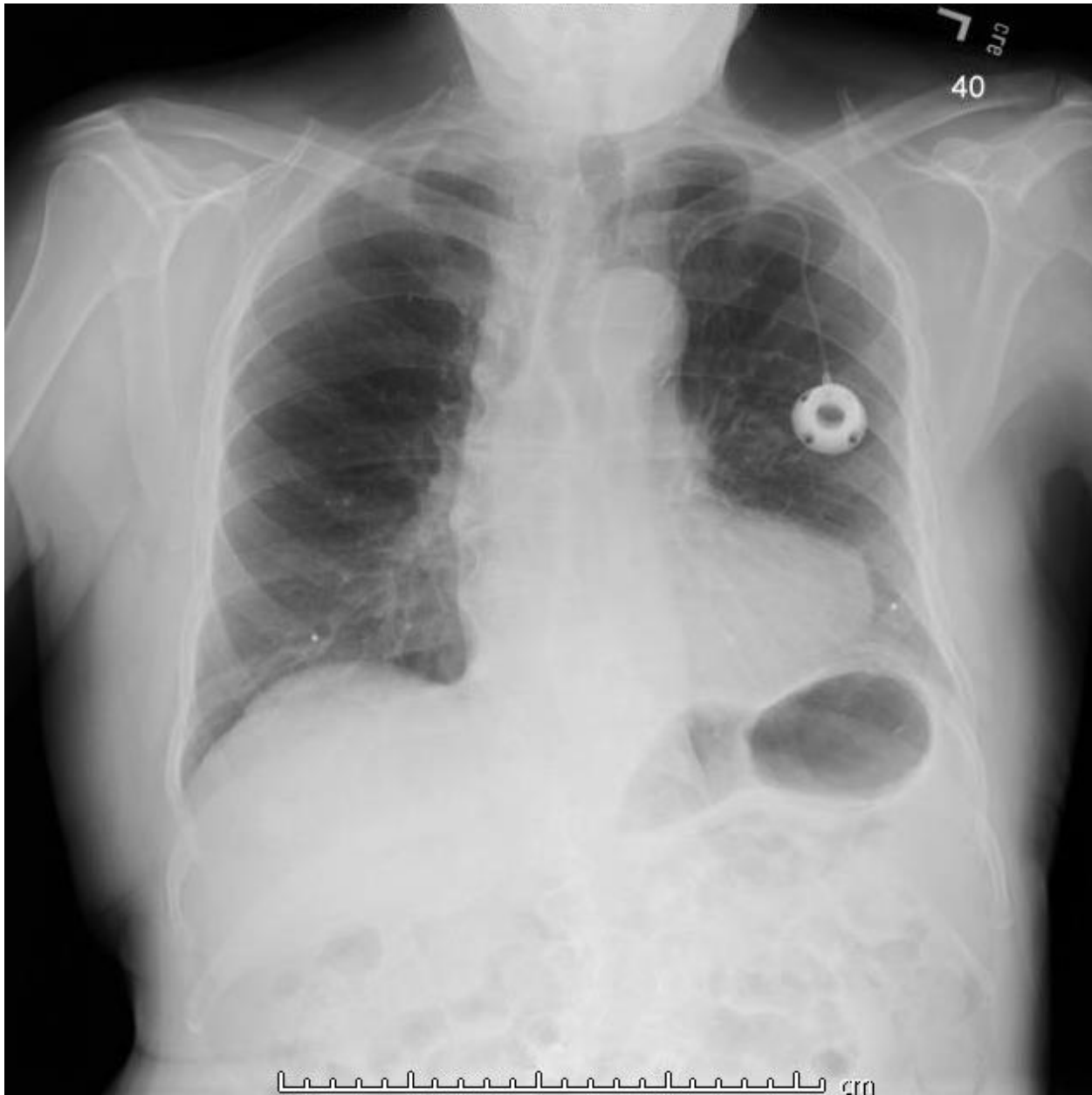
2/21/18

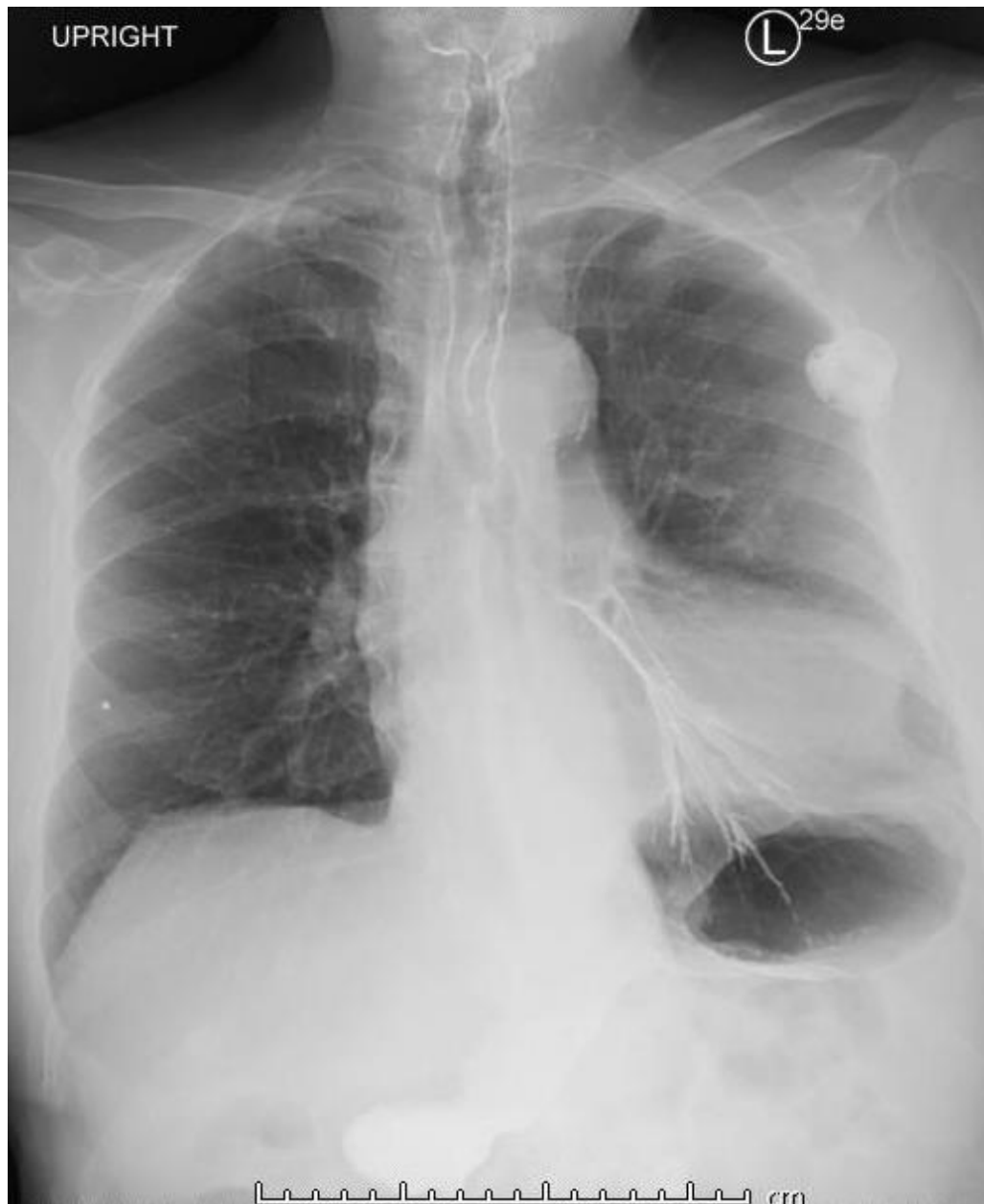

Clinical history

- 83yo man with a history of tobacco use, esophageal stricture and laryngeal cancer s/p resection and chemoradiation in 1999.
- Over the previous 1-2 months, developing left-sided ear pain
- Progressive dysphagia noted over past year
- Recent CT soft tissue neck showed asymmetric soft tissue fullness of the inferior left parapharyngeal region, hypoechoic lesion in the superior aspect of the right masseter muscle.
- Direct laryngoscopy showed irregular-appearing mass of mucosa in the left lateral hypopharynx extending into the post-cricoid region.
- Pathology showed invasive well differentiated keratinizing squamous cell carcinoma.

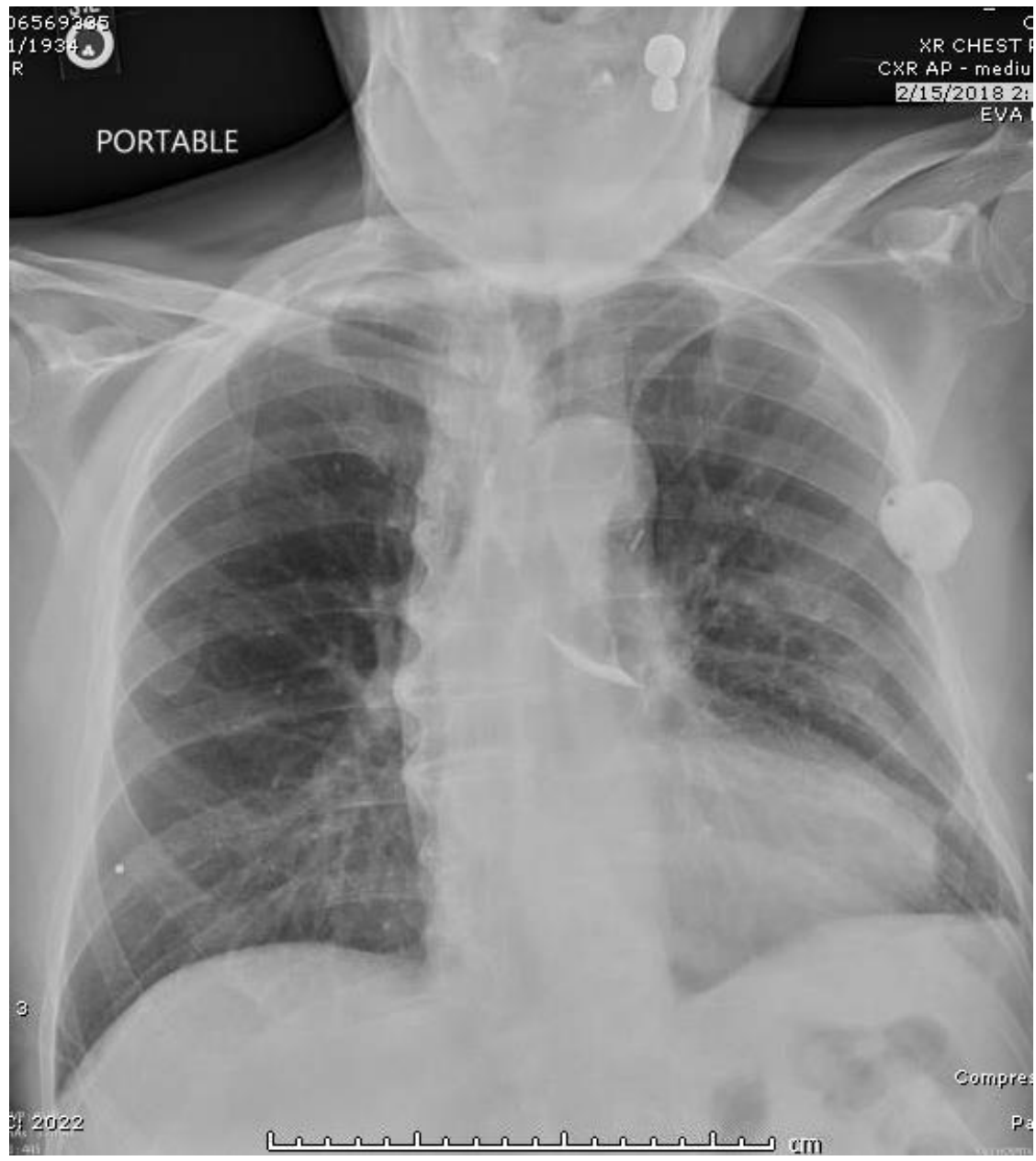

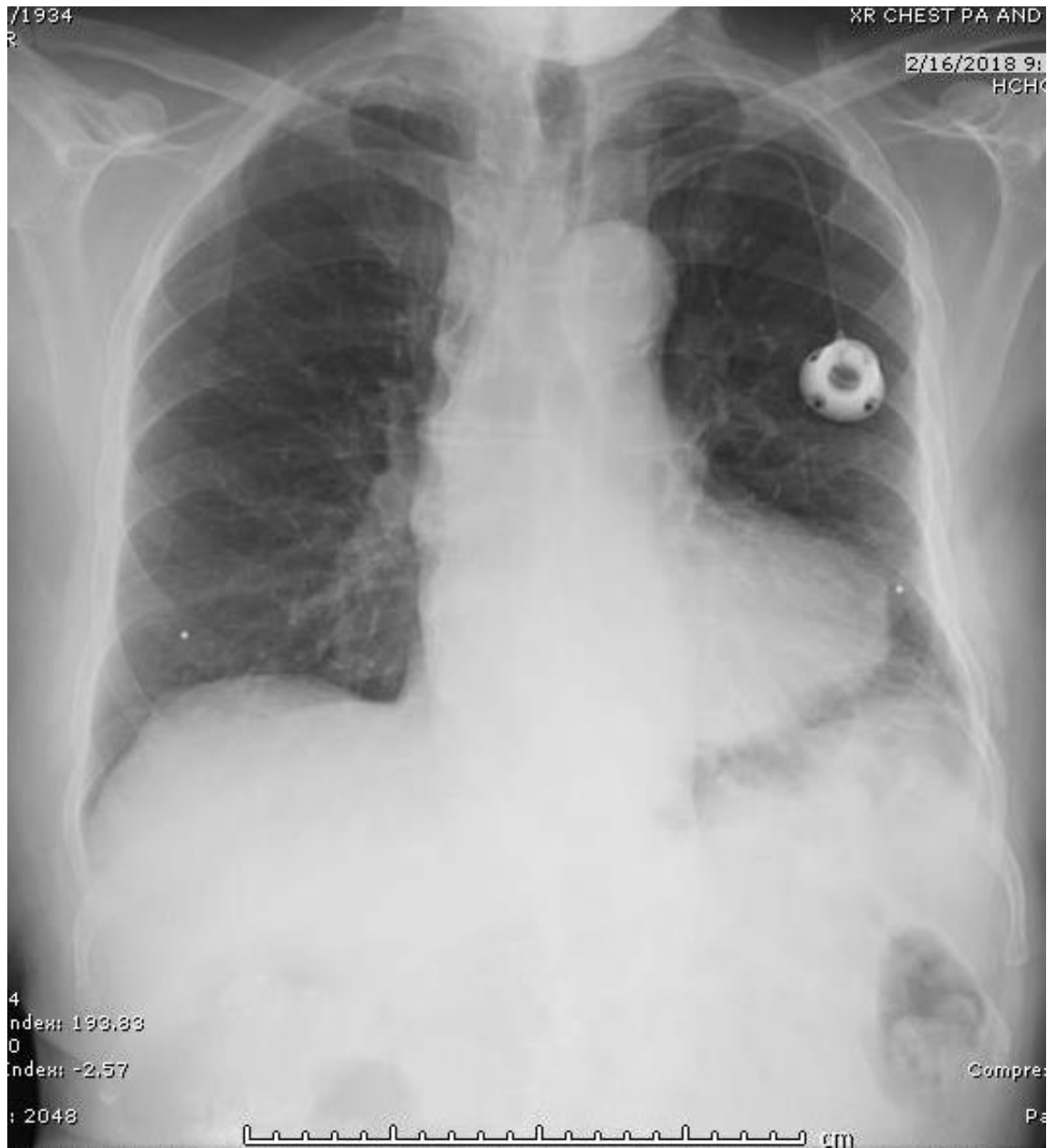




Clinical course

- Directly admitted to hospital for continuous pulse oximetry and monitoring
- Remained asymptomatic, afebrile and maintained O₂ saturation of >94% on room air
- Cleared barium on CXR overnight, but remained inpatient until previously scheduled biopsy
- Failed FEES twice with aspiration to all consistencies
- G-tube planned with IR





Barium Contrast

- Barium is a chemically inert, radio-opaque substance used for contrast
- Allergic reactions are rare, and pneumonitis is generally mild
- In contrast, water soluble contrast agents like gastrograffin can cause fluid shifts leading to pulmonary edema.
- Barium is slowly phagocytosed by alveolar macrophages
- Respiratory failure in massive aspirations is secondary to mechanical obstruction of alveoli and small airways
- Bronchoscopy can be attempted to remove as much barium as possible in such severe cases

NEJM case report



