

# RADIOLOGY CASE PRESENTATION

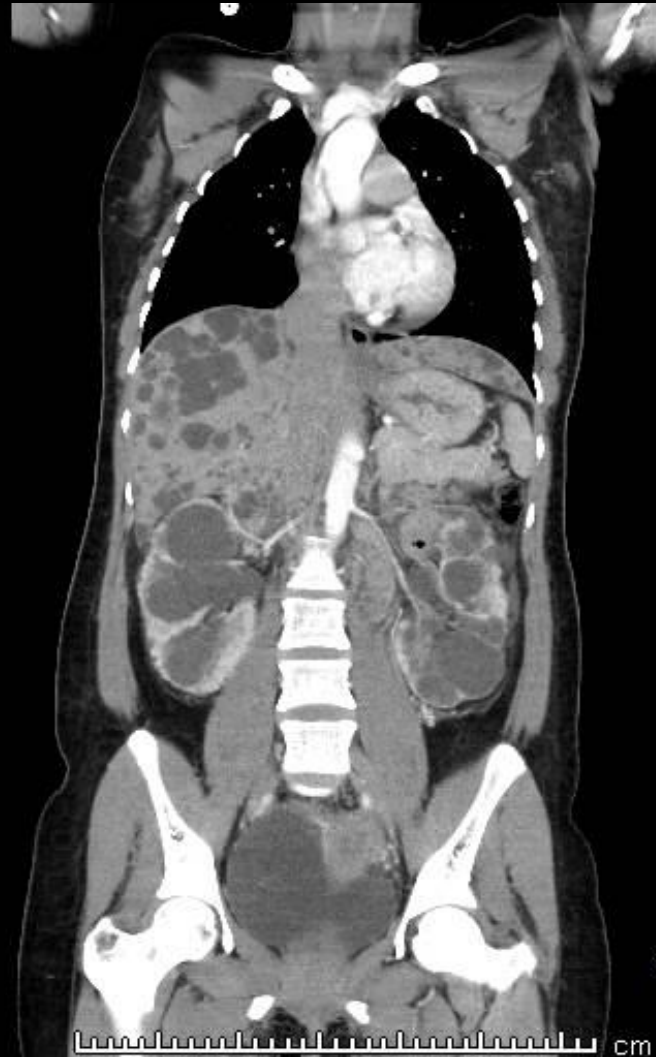BEN XU, MS4

APRIL 19, 2018

# HISTORY

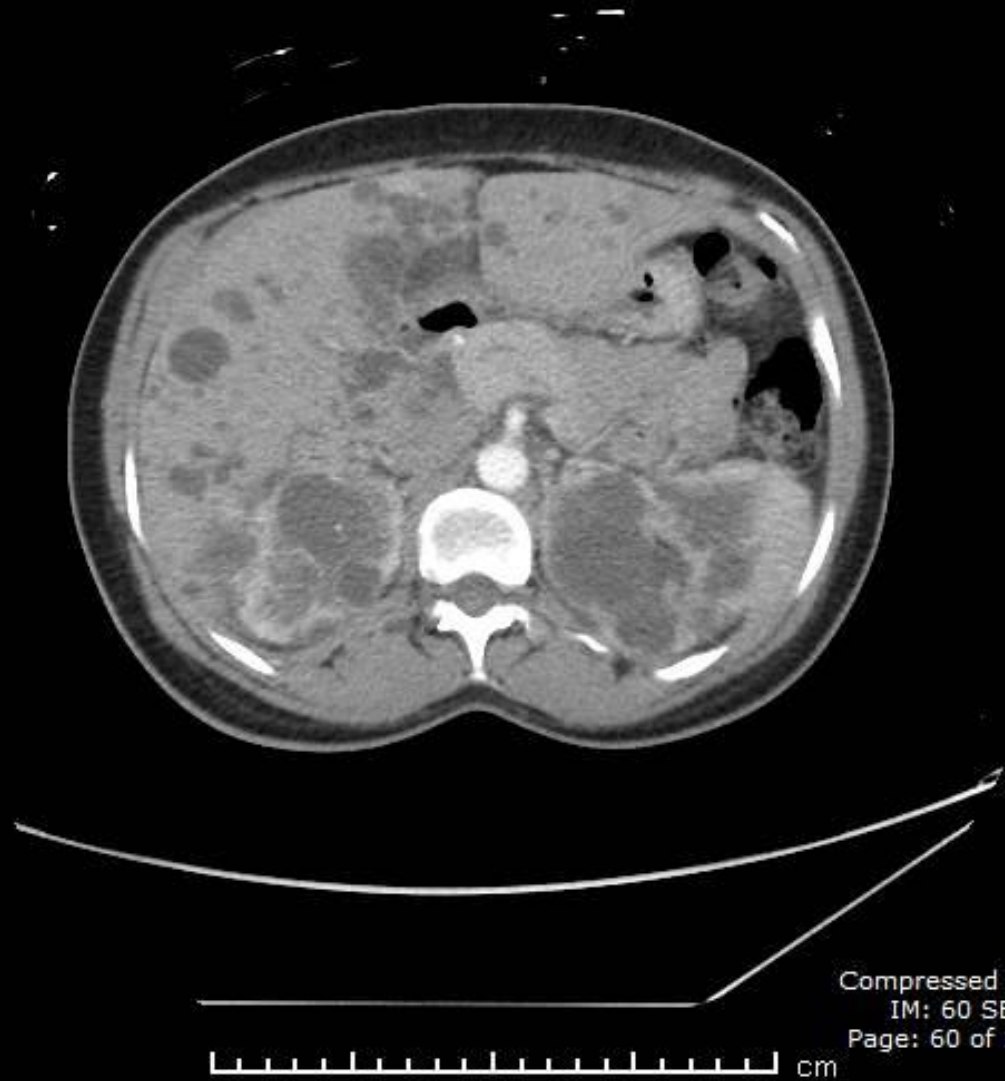
- MR is a 41 year-old female with a history of anemia who presented to the ED with a pneumonia. In addition to usual pneumonia symptoms, she also complained about a sensation that her chest being squeezed.
- PMH: anemia
- FH: mother had hereditary kidney disease, was on dialysis, and passed away

# RADIOGRAPHIC FINDINGS



Compressed 8:1  
IM: 30 SE: 601  
Page: 29 of 58

# RADIOGRAPHIC FINDINGS



# Differential diagnosis

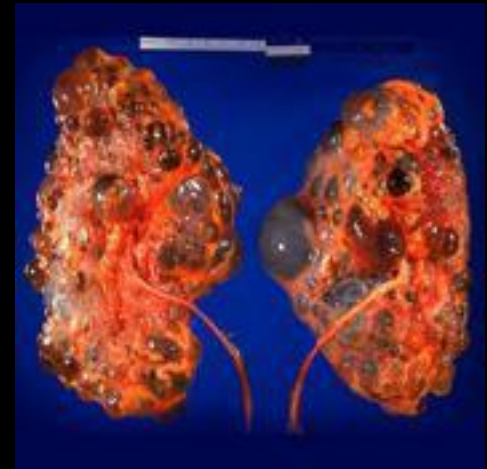- VHL disease (pancreatic cysts)
- Primary renal disease-related cysts
- Multiple incidental renal cysts
- ARPKD (enlarged kidney, cysts numerous & small, childhood onset, corticomedullary differentiation loss)
- Medullary cyst disease
- Multicystic dysplastic kidney (unilateral, non-hereditary)

# Bosniak classification system of renal cystic masses

- Septa and Calcification
- Bosniak 1: simple ~0% malignant
- Bosniak 2: minimally complex ~0-5% malignant
- Bosniak 3: intermediate ~50% malignant
- Bosniak 4: clearly malignant, solid

# Autosomal-dominant polycystic kidney disease

- Incidence of 1 in 1000, and 5% of ESRD
- Polycystin 1 (16p, 85%) and 2 (4q, 15%), involved in tubular epithelial cell adhesion and as an ion channel, respectively
- Progressive dilation and dysfunction of renal tubules



# Clinical presentation

- Flank or abdominal pain
  - Hematuria
  - Hypertension
- 
- Higher risk for pyelonephritis, urinary calculi, vascular sclerosis



# Extrarenal manifestations

- Hepatic cysts with preserved liver function
- Pancreatic and intestinal cysts, colonic diverticula, inguinal/abdominal hernia
- Valvular heart disorders
- Aneurysm: cerebral artery and carotid artery

# Management

- Symptomatic management
- Strict control of hypertension
- Screening for cerebral aneurysm
- Dialysis and transplantation

# Reference

- Merck Manual: <https://www.merckmanuals.com/professional/genitourinary-disorders/cystic-kidney-disease/autosomal-dominant-polycystic-kidney-disease-adpkd>
- Radiopaedia: <https://radiopaedia.org/articles/autosomal-dominant-polycystic-kidney-disease-1>